

Cleft Lip–Palate Deformities in Western China

Epidemiology, Surgical Reconstruction, and Cost

Travis T. Tollefson, MD; Joseph K. Wong, MD, FRCSC; Jonathan M. Sykes, MD; Wayne F. Larrabee, Jr, MD

A series of 46 procedures (42 patients) was performed on youth with cleft lip–palate deformities in Lanzhou, China. Patients' ages ranged from 6 months to 18 years. There were no short-term complications in this series, which included many advanced cases. The estimated cost per patient was US \$1590. Youth with unrepaired cleft lip–palate in western China can be treated in a cost-effective manner.

Arch Facial Plast Surg. 2006;8:234-239

The early history of cleft lip–palate repair is poorly documented. The first successful cleft lip repair was probably performed as early as 390 BC in China.¹ There are more than 300 million births per year in China and (with an incidence of 1 in 700) about 430 000 new cases of cleft lip–palate yearly. The mean cost of repair in Lanzhou is about US \$625 and in Shanghai about US \$5000. The mean income in Gansu (the poorest province) is about US \$125 per year and in Guang Tung (the wealthiest province) about US \$625 per year. Most of China's population is rural, and (to our knowledge) there are no accurate statistics on how many youth with cleft lip–palate deformity are treated. This study of a medical mission in Lanzhou documents the case complexity, surgical techniques, cost of reconstruction, and magnitude of the country's need. China is rapidly advancing economically. The wealth of China will eventually enable all of its citizens to receive needed reconstructive surgery. Until then, programs such as the Smile China Project can help close the gap.

Author Affiliations: Cleft and Craniofacial Panel, Facial Plastic and Reconstructive Surgery, Department of Otolaryngology–Head and Neck Surgery, Davis Medical Center, University of California, Sacramento (Drs Tollefson and Sykes); Smile China Project and Division of Otolaryngology–Head and Neck Surgery, Credit Valley Hospital–Peel Regional Cancer Center, Mississauga, Ontario (Dr Wong); and Larrabee Center for Facial Plastic Surgery, Seattle, Wash (Dr Larrabee).

In July 2004, a team of US and Canadian surgeons working at Gansu Province Children's Hospital in Lanzhou evaluated and treated patients from remote parts of the Gansu, Qinghai, Ningxia, and Sichuan provinces. Forty-two patients (who ultimately underwent 46 procedures) were selected for reconstructive surgery; their ages and diagnoses are given in **Table 1**. One hundred thirty-three patients were registered but did not undergo surgery on this trip because of insufficient hospital capacity. Procedures were performed on 4 consecutive days, and surgeons from Lanzhou worked closely with the team. A 2-day seminar was presented by surgeons from the United States, Canada, and China after the surgical reconstructions were completed.

SURGICAL PROCEDURES

The large number of patients who registered and the range of deformities provided an opportunity for many techniques to be shared among the host physicians and the team surgeons. The sharing of ideas, whether historical or new, was pervasive throughout the mission. The surgical team met with each patient and family on the morning before surgery for planning, photography, and securing informed

Table 1. Sex, Age, and Diagnosis Among 42 Patients*

Patient No./ Sex/Age	Diagnosis	Affected Side	Surgical Procedure
1/M/6 y	Cleft palate	NA	Palatoplasty
2/F/5 y	Cleft palate	NA	Palatoplasty
3/F/3 y	Cleft lip	Bilateral	Cleft lip repair
4/F/4 y	Cleft lip/cleft palate	Left	Cleft lip repair
5/F/3 y	Cleft lip/cleft palate	Right	Cleft lip repair
6/F/3 y	Cleft lip	Left	Cleft lip repair
7/M/4 y	Cleft lip	Bilateral	Cleft lip repair
8/M/4 y	Cleft lip	Right	Cleft lip revision
9/M/3 y	Cleft lip/cleft palate	Left	Cleft lip repair
10/M/2 y	Cleft lip/cleft palate	Left	Cleft lip repair
11/M/4 y	Cleft lip/cleft palate	Left	Cleft lip repair
12/M/4 y	Cleft lip	Right	Cleft lip revision
13/M/4 y	Cleft lip/cleft palate	NA	Palatoplasty
14/M/8 y	Cleft lip/cleft palate	Left	Cleft lip repair
15/F/18 y	Cleft lip	Right	Cleft lip revision
16/M/4 y	Cleft lip	Left	Cleft lip repair
17/F/5 mo	Cleft lip/cleft palate	Left	Cleft lip repair
18/M/5 mo	Cleft lip/cleft palate	Left	Cleft lip repair
19/M/4 y	Cleft lip/cleft palate	Left	Cleft lip repair
20/F/25 y	Cleft palate/VPD	NA	Pharyngoplasty
21/M/1 y	Cleft lip/cleft palate	Left	Cleft lip repair
22/M/14 y	Cleft lip	Left	Cleft lip repair
23/M/6 y	Cleft lip	Left	Cleft lip repair
24/M/4 y	Cleft lip	Right	Cleft lip repair
25/M/12 y	Cleft lip	Left	Cleft lip repair
26/M/5 mo	Microform cleft lip	Left	Cleft lip repair
27/M/5 mo	Cleft lip/cleft palate	Left	Cleft lip repair
28/M/1 y	Cleft lip/cleft palate	Left	Cleft lip repair
29/M/1 y	Cleft lip	Right	Cleft lip repair
30/F/15 y	Cleft palate	NA	Palatoplasty
31/M/6 y	Cleft palate	NA	Palatoplasty
32/F/11 y	Cleft lip	Left	Cleft lip repair
33/M/6 y	Cleft palate	NA	Palatoplasty
34/M/3 y	Cleft lip	Right	Cleft lip repair
35/M/4 y	Cleft lip	Left	Cleft lip repair
36/M/19 y	Cleft lip/cleft palate	Bilateral	Palatoplasty
37/M/6 y	Cleft lip/cleft palate	Left	Palatoplasty
38/F/18 y	Cleft lip	Left	Cleft lip revision
39/F/17 y	Cleft lip	Left	Cleft lip revision
40/M/17 y	Cleft lip	Bilateral	Cleft lip revision
41/F/17 y	Cleft lip	Left	Cleft lip revision
42/M/12 y	Cleft lip	Left	Cleft lip repair

Abbreviations: NA, not applicable; VPD, velopharyngeal dysfunction.

*There were 29 males and 13 females, with a mean age of 7 years; with a total of 18 isolated cleft lips, 14 cleft lips with cleft palates; 6 cleft palates; and 4 bilateral cleft lips; 24 were on the left side, 7 on the right side, 4 bilateral, and 7 involved the palate only. The total number of surgical procedures performed was 46 (8 palatoplasties, 7 cleft lip revisions, 26 cleft lip repairs, 1 pharyngoplasty, and 4 palatal fistula repairs with the cleft lip revision).

consent. The quiet and cooperative behavior of the youth during these and subsequent examinations was remarkable. Each surgeon evaluated the youth's cleft lip-palate deformity for characteristic appearances and unique qualities. The team surgeons then collaborated to develop surgical plans. The following selected cases illustrate the variety of surgical techniques used.

Most of the patients with primary unilateral cleft lip-palate were treated by means of a modified Millard rotation-advancement method. Primary cleft lip repair is traditionally performed when the patient is 3 to 4 months old. Several older patients, including a 14-year-old boy (**Figure 1**), had an unrepaired cleft lip-palate. They had

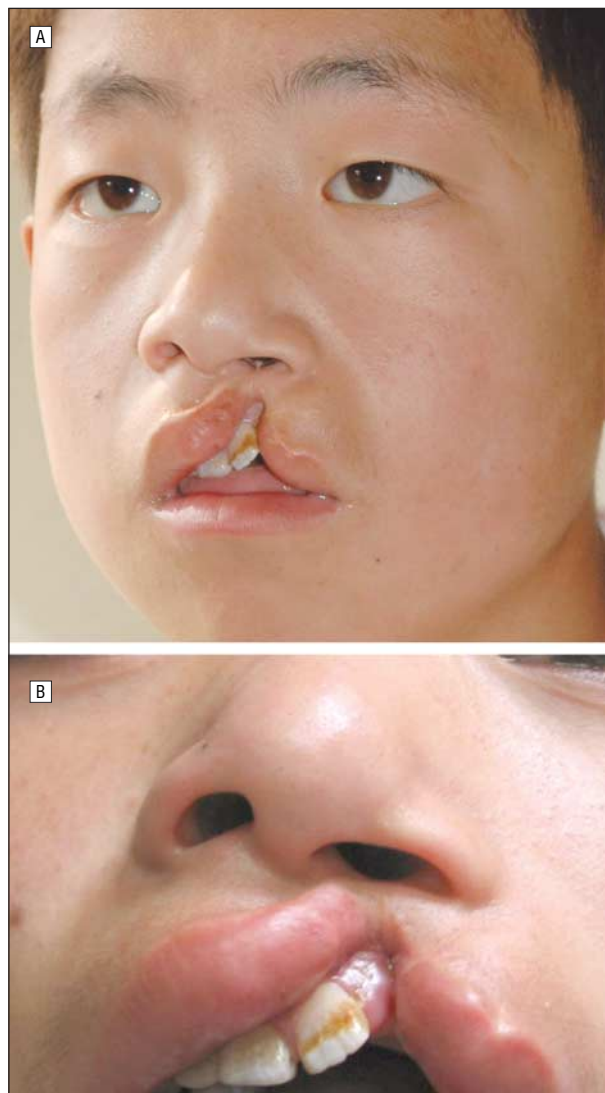


Figure 1. A, Preoperative photograph of a 14-year-old boy with an unrepaired left cleft lip, alveolus, and palate. A line of demarcation is noted on the teeth. B, Close-up intraoperative photograph.

experienced not only the effects of the physical deformity (speech, feeding, and others) but also the psychological effects of their condition. A result of delayed treatment is deterioration of anterior dentition (**Figure 2**). The exposure of teeth through the cleft lip-palate allows tooth decay that creates a line of demarcation.

Management of the nasal deformity at the time of cleft lip-palate repair is controversial. Advocates of wide soft tissue elevation and remodeling of the aberrant lower lateral cartilages are opposed by those who support addressing the nasal deformity at a later time. Based on surgeon preference, rhinoplasty techniques were used in several of the infants and older youth undergoing primary cleft lip-palate repair. In the triangle fixation suture technique, a buried horizontal mattress suture is placed from the vestibular surface of the affected ala out to the proposed alar groove. Placement of these sutures allows molding of the alar cartilage and soft tissues without resection or aggressive surgical undermining (**Figure 3**).²

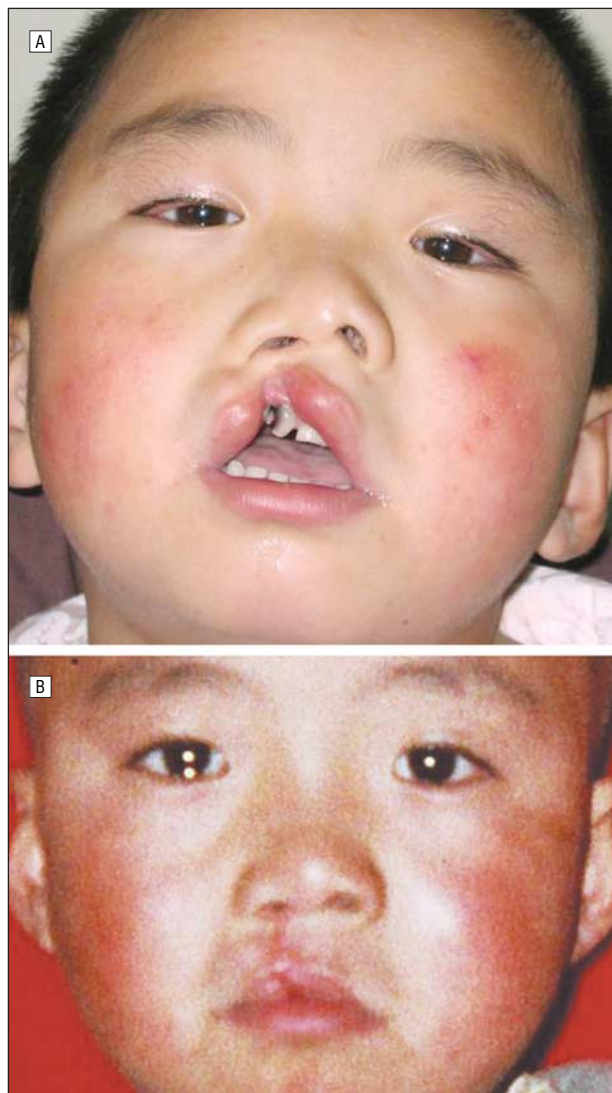

Figure 2. A, Preoperative photograph of a 4-year-old child with an unrepaired right cleft lip. Note the decay of maxillary dentition. B, Four-month postoperative photograph. The postoperative photographs were obtained during follow-up by Lu Shouchang, MD, DDS.

Different techniques of cleft lip-palate revision were used. A 4-year-old boy with a previously repaired right-sided cleft lip-palate had at least 3 identifiable abnormalities. First, lateral displacement of the cleft-side nasal base and the hooding of the ala resulted in asymmetry of the alar margin and the nostril size and shape (**Figure 4A**). Second, red lip (mucosa) was deficient at the closure site. Although the wet-dry lip junction was well aligned, fullness of the lip in the vertical and horizontal planes was lacking (**Figure 4B**). Techniques to avoid this secondary deformity at the primary repair include a white roll flap and meticulous attention to reapproximation of the orbicularis oris using a vertical mattress suture to establish balanced lip fullness. Third, the unrepaired cleft alveolus and malpositioned dentition would require bone grafting of the alveolar cleft after presurgical orthodontic preparation (**Figure 4C**). The following procedures were performed in this case: the lip scar was excised, the alar base width was set with

a deep suture, the lower lateral cartilages were dissected from the overlying nasal skin soft tissue envelope, horizontal mattress cartilage reshaping sutures were placed to create the alar groove, and lip fullness was adjusted by creating a triangular flap at the wet-dry mucosal junction to balance the transition across the incision and to camouflage the scar by breaking the straight line closure.

One of us (J.K.W.) performed a bilateral cleft lip-palate revision technique that had been taught to him by his Japanese mentor, Takuya Onizuka, MD, and co-workers.³⁻⁵ The overall goals of this technique are the following (**Figure 5**)³:

change the two scar lines of bilateral cleft lip repair into one zigzag scar line in the center of the lip. . . the prolabium is used to push up the columella and the nasal tip. This method has many advantages including an inconspicuous scar, repair of the short columella and flat nasal tip, repair of a wide nose, and repair of the whistling deformity.

Comprehensive management of cleft lip-palate disorders must also address functional speech and swallowing aspects. Two-flap and Furlow (double reverse Z-plasty) palatoplasties were performed, including a primary repair on an 18-year-old male university student with a wide complete cleft palate and an energetic young woman who routinely wore a neon green blouse to greet the team as we entered the hospital. She was still experiencing velopharyngeal dysfunction after palatoplasty and ultimately underwent a superiorly based pharyngeal flap (fish-mouth technique) without complication. The importance of these functional surgical procedures should be emphasized among younger subjects with cleft lip-palate whose persistent hyponasality may be best remedied with pharyngoplasty.

Smile China Project in 2004 offered many insights to the team members. One of the younger surgeons summarized his experience: "Personally, I was honored to gain a better understanding of beneficence, perspective, humility, cultural respect, and true appreciation. I feel that this experience also served to adjust my surgical 'comfort template.' The next time I am confronted with a less than ideal operating room condition (inexperienced staff, inadequate instruments, poor lighting, etc), I hope to react with innovation, patience, and adaptation."

COST ANALYSIS

It is difficult to compare the expenses associated with these types of missions because of variables such as mission duration, transportation costs, and local support facilities. Nevertheless, analysis of the cost per patient allows some comparison of alternative methods of delivering the same care. On our trip, Smile China Project provided approximately US \$370 per patient to cover hospital and anesthesia expenses. **Table 2** gives the basic costs for the 4 operating surgeons (1 [J.K.W.] from Canada) and 2 Canadian nurses who were involved in patient care. The value of donated supplies, medicines, and other financial support is included in the analysis because, whether paid directly or by donations, they represent real costs.

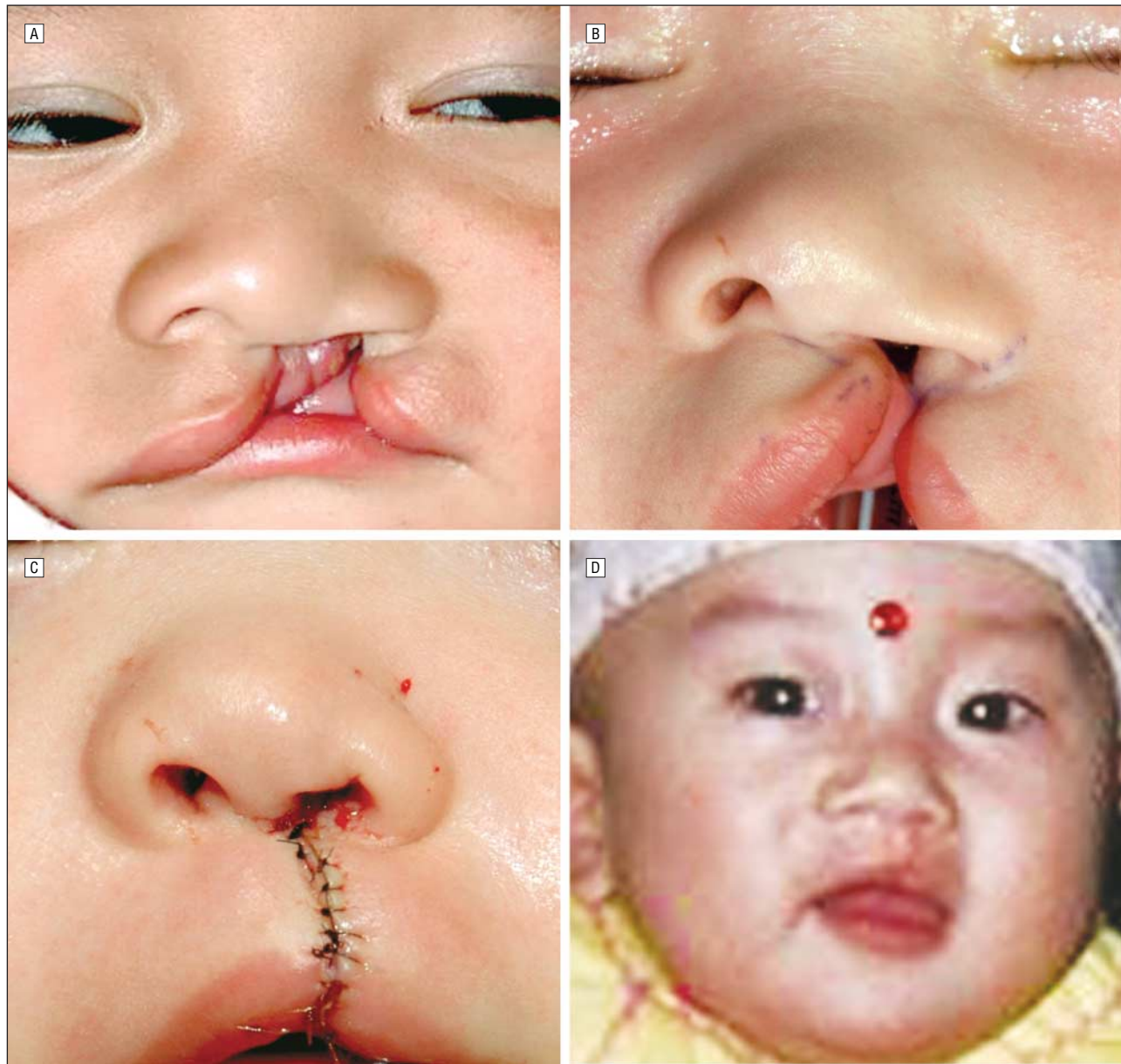

Figure 3. A, Preoperative photograph of an 11-month-old child with a left cleft lip-palate that includes the alveolus. Note the left alar hooding; columellar and caudal septal deflection to the noncleft side; displacement of the alar base laterally, posteriorly, and inferiorly; and asymmetric tip, as represented by the light reflection on the right tip-defining point only. B, Intraoperative view before the left cleft lip repair and tip rhinoplasty. C, Intraoperative view immediately after the cleft lip repair and placement of the triangle fixation suture to enhance the left alar crease and to reposition the lower lateral cartilage. D, Four-month postoperative view.

COMMENT

In western China, a substantial number of youth await cleft lip-palate repair. Procedures offered by missions such as Smile China Project result in a small decrease in the overall numbers but are life changing for the individuals involved. It is difficult to measure the long-term benefits of the education provided by such missions to the physicians in China, among whom the cost per patient of approximately US \$750 provides education and training. By North American standards, this is cost-effective but represents a large expenditure in China.

An essential component of these programs is the host country practitioner who provides postoperative care and

as much long-term consultation and follow-up as possible. Lu Shouchang, MD, DDS, an oral and maxillofacial surgeon from The People's Hospital of Gansu Province, provided such care and an evaluation of outcomes in this mission. Surgical outcomes should include not only the presence or absence of short-term complications but also a long-term assessment of speech, hearing, and craniofacial conditions. Hard and soft tissue cephalometrics and dental arch elevation strips (eg, the Goslon yardstick) are useful measures, but consistent longitudinal photographs are practical standards.

Accurate medical records are critical to evaluating and improving the progress of missions such as Smile China Project. For example, outcomes in the United States have

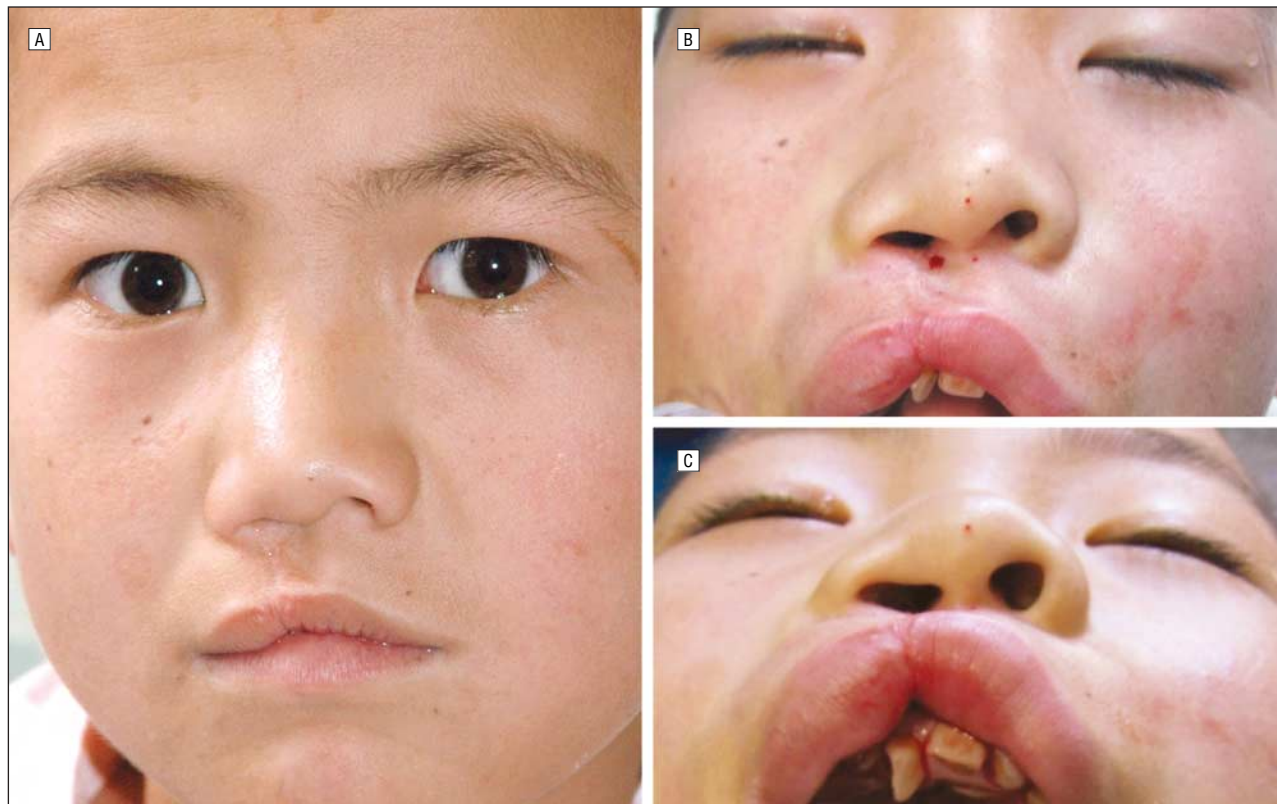

Figure 4. A, Nine-year-old boy with a repaired right cleft lip demonstrating several secondary abnormalities, including lateral displacement of the cleft-side nasal base and hooding of the ala, which resulted in asymmetry of the alar margin and the nostril size and shape. B, Close-up photograph demonstrating the lack of white roll continuity and deficiency at the lip closure site. C, Base view demonstrating the lateral and anterior displacement of the right alar base, unrepaired right cleft alveolus, and malpositioned anterior dentition.

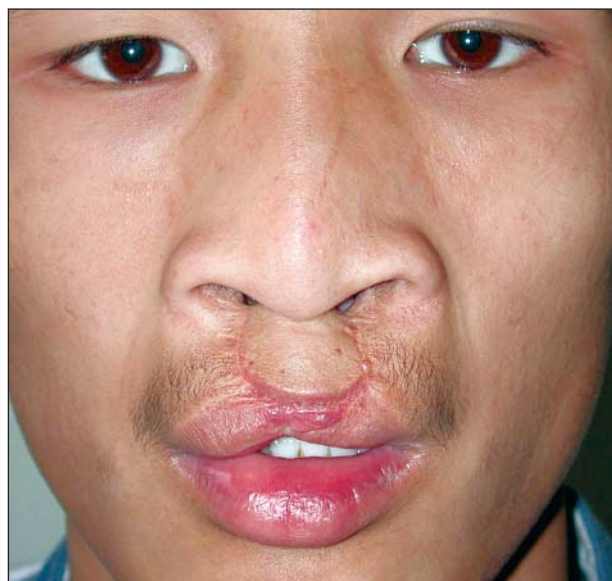

Figure 5. Preoperative photograph of an 18-year-old patient with a previously repaired bilateral cleft lip deformity consisting of a wide philtrum, deficiency of muscle and lip fullness (lack of tubercle), peaked vermillion cutaneous junctions at the Cupid bow, lack of nasal sill fullness, widened alar bases, and lack of nasal projection and definition. Note the lack of hair in the prolabial segment. A 1-scar technique by Onizuka et al⁹⁻⁵ was used. Postoperative photographs were unavailable.

shown that more experienced surgeons achieve better outcomes.⁶ This type of analysis is impossible without detailed medical records.

Table 2. Expenses of Smile China Project in 2004 for 46 Procedures

Expense	Cost, US \$
Airline tickets (international and domestic) for 11 persons	19 382
Hotel accommodations (6 rooms)	5 590
Hospital and anesthesia fees (donated)	17 165
Surgical equipment and supplies	9 551
Sutures (donated)	4 290
Medications (92% donated)	17 165
Total	73 143
Estimated cost per procedure	1 590

Many organizations provide pro bono reconstruction surgery around the globe (eg, Face to Face is a program of the American Academy of Facial Plastic and Reconstructive Surgery that sponsors many missions). Unlike most public health problems, cleft lip-palate and related surgical reconstructions are amenable to this approach. Brief objective reports of these missions not only stimulate interest but also provide data to ensure that future missions are productive and cost-effective.

Accepted for Publication: March 23, 2006.

Correspondence: Travis T. Tollefson, MD, Cleft and Craniofacial Panel, Facial Plastic and Reconstructive Sur-

gery, Department of Otolaryngology–Head and Neck Surgery, Davis Medical Center, University of California, Sacramento, 2521 Stockton Blvd, Suite 7200, Sacramento, CA 95817 (travis.tollefson@yahoo.com).

Funding/Support: This study was supported by Smile China Project (hospital and anesthesia fees), Health Partners International of Canada (medications), Tyco Health Care Group (sutures), and Tour East (airline tickets).

Disclaimer: Dr Larrabee is the editor of the *Archives of Facial Plastic Surgery*. He was not involved in the editorial evaluation or decision to accept this article for publication.

Acknowledgment: We acknowledge the significant donations from Dr Wong in the form of supplies and official dinners.

REFERENCES

1. Boo-Chai K. An ancient Chinese text on cleft lip. *Plast Reconstr Surg*. 1966;38:89-91.
2. Bagatin M, Larrabee WF Jr. Secondary reconstruction of the bilateral cleft lip: a technique that emphasizes the importance of nasalis muscle. *Facial Plast Surg*. 1996;4:413-421.
3. Onizuka T, Hosaka Y, Satoh K. Aesthetic camouflage of bilateral cleft lip scars: technical revisions. *Aesthetic Plast Surg*. 1993;17:23-29.
4. Onizuka T, Hosaka Y, Sumiya N, Satoh K, Haraguchi K. Aesthetic camouflage of bilateral cleft lip scars. *Aesthetic Plast Surg*. 1987;11:241-247.
5. Onizuka T. A new method of elongation of the columella nasi for bilateral cleft lip. *Keisei Geka*. 1970;13:529-533.
6. Shaw WC, Dahl E, Asher-McDade C, et al. A six-center international study of treatment outcomes in patients with clefts of the lip and palate. *Cleft Palate Craniofac J*. 1992;29:413-418.

Announcement

Identifiable Patient Photographs

Please do not send masked photographs of patients.

Until the late 1980s, placing black bars over the eyes of patients was accepted as a way to mask the identities of patients in photographs when consent to publish their photographs was not or could not be obtained. However, bars across eyes do not always mask identities and should not be used. . . .

Therefore, when photographs of faces or identifiable body parts or detailed case descriptions are included in a manuscript, authors should obtain written permission from the identifiable subject (or a legally authorized representative) to publish the photograph or case description, and send a copy of the permission to the journal.¹

Authors may obtain the Patient Consent Form from www.archfacial.com. The patient should be offered the opportunity to see the manuscript before submission. When the manuscript is submitted electronically, send the patient consent by fax to the editorial office: (206) 386-3553.

1. Iverson C, Flanagan A, Fontanarosa PB, et al. *American Medical Association Manual of Style*. 9th ed. Baltimore, Md: Lippincott Williams & Wilkins; 1998:141-142.